

# The American Journal of Sports Medicine

<http://ajs.sagepub.com/>

---

## **Complications of Bioabsorbable Suture Anchors in the Shoulder**

Aman Dhawan, Neil Ghodadra, Vasili Karas, Michael J. Salata and Brian J. Cole

*Am J Sports Med* 2012 40: 1424 originally published online August 19, 2011

DOI: 10.1177/0363546511417573

The online version of this article can be found at:

<http://ajs.sagepub.com/content/40/6/1424>

---

Published by:



<http://www.sagepublications.com>

On behalf of:



American Orthopaedic Society for Sports Medicine

**Additional services and information for *The American Journal of Sports Medicine* can be found at:**

**Email Alerts:** <http://ajs.sagepub.com/cgi/alerts>

**Subscriptions:** <http://ajs.sagepub.com/subscriptions>

**Reprints:** <http://www.sagepub.com/journalsReprints.nav>

**Permissions:** <http://www.sagepub.com/journalsPermissions.nav>

>> [Version of Record](#) - Jun 1, 2012

[OnlineFirst Version of Record](#) - Aug 19, 2011

[What is This?](#)



# Complications of Bioabsorbable Suture Anchors in the Shoulder

Aman Dhawan,\* MD, Neil Ghodadra,\* MD, Vasili Karas,\*<sup>†</sup> BS,  
Michael J. Salata,<sup>‡</sup> MD, and Brian J. Cole,\* MD, MBA

*Investigation performed at Rush University Medical Center, Chicago, Illinois*

The development of the suture anchor has played a pivotal role in the transition from open to arthroscopic techniques of the shoulder. Various suture anchors have been manufactured that help facilitate the ability to create a soft tissue to bone repair. Because of reported complications of loosening, migration, and chondral injury with metallic anchors, bioabsorbable anchors have become increasingly used among orthopaedic surgeons. In this review, the authors sought to evaluate complications associated with bioabsorbable anchors in or about the shoulder and understand these in the context of the total number of bioabsorbable anchors placed. In 2008, 10 bioabsorbable anchor-related complications were reported to the US Food and Drug Administration. The reported literature complications of bioabsorbable anchors implanted about the shoulder include glenoid osteolysis, synovitis, and chondrolysis. These potential complications should be kept in mind when forming a differential diagnosis in a patient in whom a bioabsorbable anchor has been previously used. These literature reports, which amount to but a fraction of the total bioabsorbable anchors implanted in the shoulder on a yearly basis, underscore the relative safety and successful clinical results with use of bioabsorbable suture anchors. Product development continues with newer composites such as PEEK (polyetheretherketone) and calcium ceramics (tricalcium phosphate) in an effort to hypothetically create a mechanically stable construct with and improve biocompatibility of the implant. Bioabsorbable anchors remain a safe, reproducible, and consistent implant to secure soft tissue to bone in and about the shoulder. Meticulous insertion technique must be followed in using bioabsorbable anchors and may obviate many of the reported complications found in the literature. The purpose of this review is to provide an overview of the existing literature as it relates to the rare complications seen with use of bioabsorbable suture anchors in the shoulder.

**Keywords:** suture anchor; complications; biomaterials; rotator cuff; labrum

With the evolution of arthroscopy of the shoulder, suture anchors have become an instrumental implant, allowing surgeons to reliably coapt and maintain soft tissue to bone repair until successful healing occurs. Various devices have been used in the past for labral fixation, including cannulated screws, transglenoid sutures, glenoid tacks, metallic staples, and metallic screws.<sup>57</sup> The metallic suture anchor with non-absorbable sutures was used frequently for labral and glenohumeral soft tissue fixation. Despite the initial encouraging results, numerous reports of metallic suture anchor-associated complications are found throughout the literature.<sup>19,43</sup>

Bioabsorbable fixation devices were developed as an alternative to metallic anchors.<sup>45</sup> The ability of these anchors to absorb over time may reduce complications

associated with migration or interference during revision surgery and allows for decreased artifact during advanced imaging.<sup>7</sup> Several authors have recommended a transition from the use of metal to bioabsorbable anchors in specific situations given their theoretical benefits.<sup>38</sup> The ability of bioabsorbable biomaterial anchors to alter the mechanisms of failure of suture anchors (suture-tissue interface, suture-anchor interface, and anchor-bone interface), frequency with which this occurs, or severity of these failures is not well understood. With this in mind, we performed a selective review of reported complications associated with bioabsorbable anchor use about the shoulder. We sought to evaluate the similarities and differences between different anchor types, the various modes of failure of these anchors, and what could be done to help minimize these failures.

## EVOLUTION OF BIOABSORBABLE ANCHORS

Healing of soft tissue to bone requires a biomechanically stable construct for up to 12 weeks, independent of the material from which the suture anchor is made.<sup>13,50</sup> If these biomechanical requirements are not met, healing may not occur and the repair may fail.<sup>13,50</sup> Suture anchors were initially metallic and nonabsorbable and, when first introduced, contributed to a revolution in surgery of the wrist, elbow, and, in particular, the shoulder. These anchors

<sup>†</sup>Address correspondence to Vasili Karas, BS, Division of Sports Medicine, Rush University Medical Center, 1611 W Harrison, Suite 300, Chicago, IL 60612 (e-mail: vasili.karas@gmail.com).

\*Rush University Medical Center, Chicago, Illinois.

<sup>‡</sup>University Hospitals Case Medical Center, Cleveland, Ohio.

One or more of the authors has declared the following potential conflict of interest or source of funding: Dr Cole is a consultant for Arthrex Inc (Naples, Florida), DJ Orthopaedics, Zimmer, Genzyme, and DePuy. Rush University Medical Center receives fellowship support from Smith & Nephew.

were initially single loaded with simple polyester braided sutures and offered an alternative to transosseous techniques for securing soft tissue to bone. Because of the low profile of implant and instrumentation, suture anchors allowed arthroscopic preparation and placement and were instrumental in the evolution of arthroscopic shoulder repair techniques. These initial metallic suture anchors demonstrated initial pull-out strengths similar to that of transosseous fixation.<sup>24,34</sup> Laboratory studies demonstrated that the first generation of anchor fixation failed most commonly by suture rupture through the metallic eyelet.<sup>35</sup> Initial reports using metallic anchors for soft tissue fixation in and about the shoulder were promising; however, later investigations demonstrated complications.<sup>25,38</sup> Goeminne and Debeer<sup>21</sup> describe a migration event in a patient 7 years postoperatively in which metal anchors placed for labral reconstruction migrated into the glenohumeral joint, which resulted in significant intra-articular mechanical damage.

Complications included loosening, migration, incarceration of the metal implant within the joint, chondral damage, and interference with imaging studies, notably MRI.<sup>19,38</sup> Because of the reported complications and mounting concern with use of metallic suture anchors about the shoulder, bioabsorbable devices were developed as an alternative method of securing soft tissue to bone.

The ideal bioabsorbable suture anchor would have the mechanical strength and pull-out profile of a metallic anchor, especially in the first 12 to 16 weeks; be biologically compatible with the soft tissue and bone; and result in very few long- and short-term complications. Speer et al<sup>46</sup> identified 4 important criteria that must be met for a bioabsorbable implant used during shoulder arthroscopy: (1) The implant must have an initial fixation strength to coapt the soft tissues to bone, (2) the material property and time to degradation of the implant must allow satisfactory strength while the healing tissues are regaining mechanical integrity, (3) the implant must not degrade too slowly to avoid the complications of metallic implants, and (4) the materials of the implant must not cause toxicity, antigenicity, pyrogenicity, or carcinogenicity.

## MATERIAL PROPERTIES AND DESIGN OF BIOABSORBABLE SUTURE ANCHORS

There are more than 40 types of different bioabsorbable polymers that have been developed for use in surgery, but the most commonly used are polyglycolic acid (PGA), polylactic acid enantiomers (PLLA), and poly-D-L-lactic acid copolymer polyglycolic acid (PDLLA-co-PGA). Early absorbable implants were composed of mostly PGA polymers that have the potential to degrade very rapidly, often losing significant mechanical strength in the first 3 to 4 weeks after implantation in a physiologic environment. One of the first bioabsorbable implants developed for soft tissue fixation to bone (SureTac) was composed of PGA and trimethylene carbonate copolymer. Indeed, reports demonstrated rapid loss of strength in the first 4 weeks after implantation that led to associated loose bodies and synovitis in the shoulder.<sup>46</sup>

TABLE 1  
Degradation Time of Biomaterials Used  
in Bioabsorbable Suture Anchors

Bioabsorbable Anchor Material	Degradation Time, mo
Polyglycolic acid (PGA)	4 <sup>16</sup>
Poly(lactic acid enantiomers (PLLA)	>20 <sup>48</sup> ; >32 <sup>55</sup>
Poly-D-L-lactic acid copolymer polyglycolic acid	12 <sup>48</sup> ; 60 <sup>28</sup>
Poly-D-L-lactic acid (PDLLA)	10-14 <sup>48</sup>

Each polymer has a different degradation profile (Table 1). With rapid degradation, the release of monomer overwhelms the body's ability to clear the by-products, leading to possible foreign body reaction, cyst formation, synovitis, allergic response, and loose foreign bodies. The acidic nature of these by-products can also interfere with bone formation as hydroxyapatite is the preferred form of calcium phosphate in the body at higher pH values.<sup>40</sup> The optimum time frame for degradation of polymers has yet to be determined as in vitro times have not been consistent with in vivo degradation. In clinical studies, PLA and PGA have been shown to persist in vivo for up to 5 years and result in complete resorption at 7 and 10 years, respectively.<sup>6,29,40,53</sup> With complete resorption of the screw, partially calcified fibrous tissue rather than bone formed within the screw track. At 12 weeks in PLA implants, there was no host tissue penetration at the bone-implant interface.<sup>52</sup>

The process by which a bioabsorbable anchor is absorbed is complex. These implants degrade in vivo by nonspecific hydrolytic clipping of ester bonds. As this hydrolysis progresses, microfractures occur within the implant, causing further hydrolysis until the monomers are able to be phagocytized by local macrophages and polymorphonuclear leukocytes.<sup>1,34</sup> Depending on the molecular weight and degree of crystallinity, mechanical properties of different bioabsorbable implants will behave differently in a physiologic environment.<sup>44</sup> This molecular weight and crystallinity can be altered to optimize the initial strength and length of time of resorption of an implant. Other variables being equal, the higher degree of crystallinity within a bioabsorbable material, the more slowly it will degrade and the longer it will maintain its strength. The PLLA implants have a reported degradation time between 10 to 30 months, depending on the stereoisomers. There are concerns that complete degradation of PLLA may require several years and that osseous replacement may never be complete.<sup>5,22,34</sup> Copolymers of lactide and PGA have been added to implants made of PLLA to increase their amorphous nature and to help reduce the degradation time.

More recently, calcium ceramic materials made of tricalcium phosphate, often along with several other polymers, have been developed for use in suture anchor materials. Ceramics are commonly used in orthopaedic applications to fill bone voids because they have a mineral content similar to that of natural bone, macroporosity and microporosity conducive to osteoconductivity, compressive strength, dissolution, and biocompatibility. Ceramic

TABLE 2  
Complications With Use of Bioabsorbable Suture Anchors<sup>a</sup>

Author	No. of Cases	Bioabsorbable Anchor Material	Surgical Procedure	Complications
Athwal et al <sup>2</sup>	4	PLLA	SLAP, Bankart reconstruction	Osteolysis and arthropathy
Glueck et al <sup>20</sup>	1	PDLLA	RCR	Osteolysis
Freehill et al <sup>17</sup>	10	PLLA/PDLLA	SLAP, Bankart reconstruction	Synovitis, arthropathy
Kelly <sup>26</sup>	1	PDLLA	RCR	Failed anchor and repair
Muller et al <sup>33</sup>	7	PLLA	SLAP, Bankart reconstruction	Asymptomatic
Barber <sup>4</sup>	2	PDLLA	Bankart reconstruction, RCR	Chondral injury
Boden et al <sup>8</sup>	3	PLLA	SLAP, Bankart reconstruction	Osteolysis, chondrolysis, failed repair
Sassmannshausen et al <sup>42</sup>	6	PLLA	SLAP	Failed anchors and repair, chondral injury
Banerjee et al <sup>3</sup>	3	PLLA	Bankart reconstruction	Osteolysis

<sup>a</sup>PDLLA, poly-D-L-lactic acid; PLLA, polylactic acid enantiomers; RCR; rotator cuff repair; SLAP, superior labral anterior and posterior.

compounds are composed of metallic and nonmetallic elements with predominantly ionic bonding that results in inherent toughness and brittleness. These materials combine the ceramics Beta-tricalcium phosphate to formulate a new class of ceramic materials, the biphasic calcium phosphates. This allows a controlled resorption profile using the highly crystalline and slowly absorbing HA and the amorphous Beta-tricalcium phosphate that resorbs very quickly. Zantop et al<sup>58</sup> demonstrated higher pull-out strengths and stiffness in interference screws composed of a blend of biphasic calcium phosphate and PDLA as compared with PDLA alone or even metallic screws. These ceramic composite anchors have been reported to have minimal tissue reaction and complete resorption with bone in-growth.<sup>34</sup>

Although not bioabsorbable but also biologically inert, a radiolucent polymer that is now being used as a material for manufacturing orthopaedic implants, including applications in trauma, spine, and more recently sports medicine and shoulder, is polyetheretherketone or PEEK. Polyetheretherketone is a stable, highly unreactive structure that is resistant to chemical, thermal, and radiation-induced degradation. The mechanical properties of PEEK in a physiologic environment are what, in particular, makes this material so attractive for use in orthopaedics. Polyetheretherketone is very resistant to hydrolysis and oxidation, even at elevated temperatures. These implants have proven strength with high load to failures and, at least in animal studies, have shown no evidence of cytotoxicity, irritation, or macroscopic reaction.<sup>27</sup> Several manufacturers have already begun to produce suture anchors with PEEK. No published data to date have been reported on failures or complications with implants manufactured with either biphasic calcium phosphates or PEEK. Polyetheretherketone offers the advantages of excellent postoperative imaging and stable fixation without the complications associated with degradation of polymer.<sup>9-11</sup>

In animal studies, PEEK implants have shown no acute inflammatory response but, similar to metals, have shown poor osteointegration.<sup>49</sup> This decreased bone-implant interaction is due to the inherent inertness and hydrophobicity of PEEK, which hinders protein-cell adhesion.<sup>12,27,36</sup>

## LITERATURE REVIEW

We performed a selective literature review using searches from MEDLINE and a Boolean language strategy to identify bioabsorbable suture anchor complications in all the English-language literature (Table 2). We also performed a search using this same database to evaluate select studies assessing properties of similar biomaterials, such as calcium composites and PEEK, now being used for manufacturing of suture anchors. We excluded articles that discussed joints other than the glenohumeral joint. Articles were selected based on their contributions to our current understanding of the basic science, clinical treatment of shoulder disorders, or historical importance. We then selected 34 pertinent studies as well as 2 data reports (US Food and Drug Administration<sup>51</sup> and Millennium Research Group<sup>32</sup>).

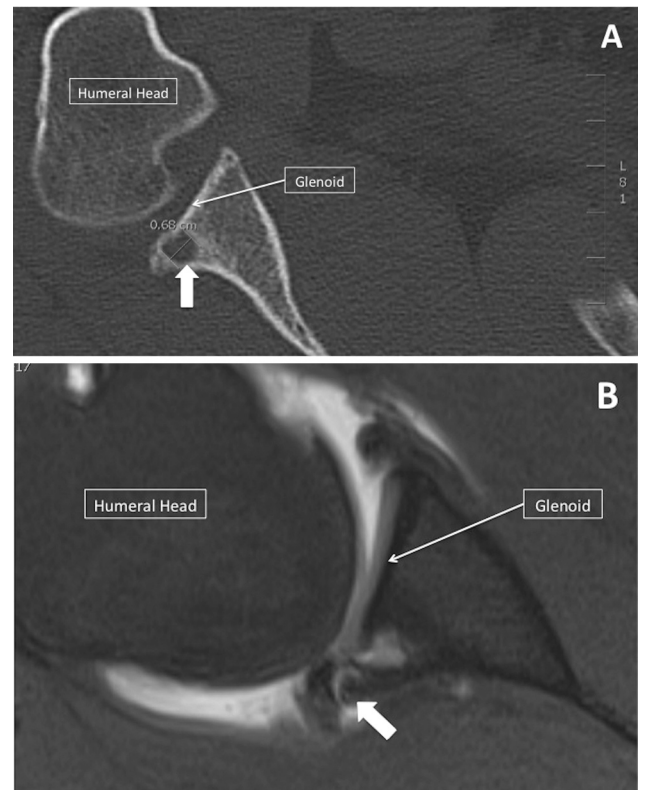
Complications and failures of bioabsorbable anchors, although rare, do occur. Freehill et al<sup>17</sup> noted a 19% complication rate (10/52) in patients who underwent shoulder stabilization with PLLA tacks. All 10 patients presented within 8 months of the index surgical procedure with complaints of pain and stiffness. On repeat arthroscopy, all patients had synovitis, 9 patients had implant debris, and 6 had evidence of full-thickness chondral injury. After repeat arthroscopy, debridement, and lavage, 7 patients reported excellent results, whereas the 3 patients who had chondral damage did not experience significant pain relief. Sassmannshausen et al<sup>42</sup> reported on a series of 6 patients with failed bioabsorbable tacks made of PLLA used for superior labral repair. All patients had MRI identification of the broken or dislodged tacks and required repeat arthroscopic reevaluation for fragment removal, evaluation of the biceps anchor, and reestablishment of the superior labrum. All patients in this series had minimal if any healing of the previous labral repair, and 2 (of 6) had significant chondral injury, presumably from the broken or dislodged anchor. As only half the patients in this series had an identifiable reinjury event, the authors concluded that even routine rehabilitation and activities of daily living may be adequate to cause implant failure. These authors recommend that surgeons who use bioabsorbable implants be aware of the potential complications and keep this high on the differential diagnosis when evaluating a patient in persistent pain, and especially with mechanical



symptoms, in the postoperative period. As the complications were all associated with use of a bioabsorbable tack, the authors stated that the use of bioabsorbable anchors instead should be considered. Magnetic resonance imaging may be helpful in making the diagnosis of a failed anchor, and subsequent arthroscopy may be required.<sup>42</sup>

Kelly<sup>26</sup> reported on a 77-year-old patient whose rotator cuff repair failed due to disintegration of a PLLA anchor at the junction of the bioabsorbable screw and the suture eyelet. In 2007, Barber<sup>4</sup> reported on 2 cases of complications with the use of bioabsorbable anchors. Both presented as squeaking or painful shoulders and were the result of part of the bioabsorbable anchor becoming a loose body within the joint. In 1 case, the polyester suture eyelet from the anchor had separated from the biodegradable body and worn through the articular cartilage on the posterior humeral head. The cause of the second case was presumed to be anchor degradation and subsequent repeated cyclic stress, which resulted in failure of the anchor just below or through the inferior suture eyelet and in the upper portion of the screw threads. This resulted in a loose body that was removed during a subsequent surgery. Of note, this anchor was used in the subacromial space for rotator cuff repair but was retrieved as a loose body in the glenohumeral joint. This migration into the glenohumeral joint can occur through an unhealed portion of the rotator cuff, through the rotator interval, or if the medial portion of the repair does not heal down to bone exposing the anchor insertion.<sup>4</sup> These cases illustrate the potential for glenohumeral loose bodies with the use of biodegradable suture anchors and nonabsorbable eyelet posts, even when used in the subacromial space. These complications may occur with use of (1) the combination of nonabsorbable suture with absorbable anchors made from copolymers with faster degradation profiles, (2) anchor placement in which a portion of the anchor eyelet or upper portion of the anchor may become exposed, and (3) the combination of absorbable anchors and more aggressive rehabilitation programs. In all of these situations, as the biodegradable anchor resorbs, the anchor eyelet may separate and become a loose body if subjected to cyclic stress.<sup>4</sup> Notably, the issue of suture leading to articular cartilage injury is exceptionally rare and must be taken in the context of the precedence of nonabsorbable sutures commonly used in an intra-articular setting such as during meniscal repair, which has an excellent safety record.<sup>14</sup>

Boden et al<sup>8</sup> recently reported a case series of 3 anchor-related complications out of a total of 22 patients who had capsulolabral repairs. Each patient had a mean of 3 PLLA bioknotless anchors placed and mean follow-up of 18 months. These 3 patients had complaints of shoulder pain with associated capsulolabral detachment, osteolysis surrounding the anchors, and chondrolysis (Figure 1). All osteolytic areas were measured within 5 mm from the original drill holes. In 2 of 3 patients, the glenohumeral articular surfaces contained areas of fissuring with partial-thickness chondral defects. The authors note that patient symptoms began at 11 to 15 months after surgery and correlated with the time frame at which PLLA begins to degrade. The authors hypothesized that the resultant synovitis and alteration in joint



**Figure 1.** A, axial CT scan of the right glenohumeral joint. The white arrow points to posterior glenoid cyst at the site of previous anchor placement. B, axial T2-weighted MRI view of the right glenohumeral joint. The white arrow points to area of increased signal intensity at the site of previous anchor placement.

fluid milieu from the degradation by-products may contribute to the possible chondral damage.

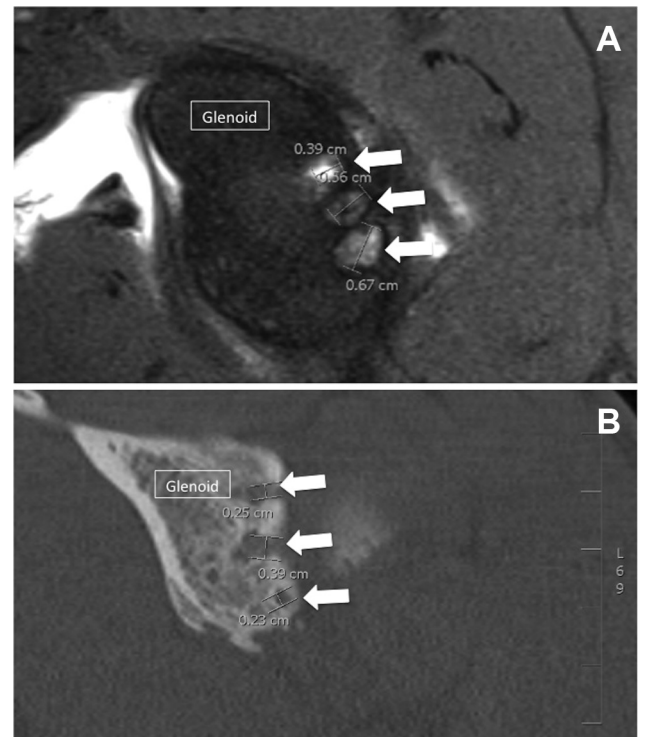
Cystic resorption, osteolysis, and arthropathy have been described with use of bioabsorbable suture anchors (Figure 2). Although this may in part be due to a mechanical origin, there is concern about the biologic and resorptive environment and interaction with the surrounding bone and tissue that are causing or at least contributing to this phenomenon. Osteolysis and arthropathy after the use of bioabsorbable suture anchors composed of PLLA were reported by Athwal et al.<sup>2</sup> Four patients were discussed, and all had repeat shoulder arthroscopy between 3 and 18 months after the index surgery. During repeat arthroscopy, all 4 patients were found to have extensive cartilage destruction on both the glenoid and humeral head, loose bodies, 1 or more loose anchors, and reactive synovitis. Spoliti<sup>47</sup> reported on a 25-year-old female competitive volleyball player who had failure of type II superior labral anterior and posterior (SLAP) repair secondary to degradation and osteolysis surrounding a bioabsorbable suture anchor. Histologic examination of the tissue harvested from the bony defect in the area of the resorbed anchor demonstrated a foreign body granuloma. The repair was revised with a nonabsorbable suture

anchor.<sup>47</sup> Muller et al<sup>33</sup> reported on 7 cases of glenoid osteolysis after shoulder stabilization procedures using PLLA anchors. None of these patients were symptomatic, showed progressive arthritis, or required repeat surgery. Glueck et al<sup>20</sup> reported on a 20-year-old National Collegiate Athletic Association Division I football defensive back who also experienced asymptomatic osteolysis around the site of insertion of PLLA bioabsorbable suture anchors at follow-up 8 months postoperatively. Because the lytic reaction was seen surrounding the anchors used to repair a rotator cuff tear and not the anchors (also PLDLA) that were placed in the glenoid for SLAP repair, the authors theorized a mechanical cause, rather than biological, for the osteolysis seen. In a recent case report, Nusselt et al<sup>37</sup> described an intraosseous foreign body granuloma in the humeral head after rotator cuff repair with a PLLA suture anchor. The authors provided several possible explanations for the granuloma formation, including implant alteration due to sterilization, focal necrosis due to drilling, and micro-motion.

Banerjee et al<sup>3</sup> report on 3 athletes who sustained glenoid rim fractures through osteolytic defects in the glenoid after labral repair using bioabsorbable anchors. In all 3 of these cases, CT/MRI demonstrated the glenoid rim fractures through the cystic areas where bioabsorbable anchors had been previously placed. The contributing bone loss prevented arthroscopic revision, and the authors performed a modified open Latarjet procedure to address the osseous insufficiency. The authors recommended that the level of contact athletic participation should be considered when choosing the type of anchor for anterior labral stabilization as the cystic resorption and osteolysis that may develop after use of biodegradable anchors may not be well tolerated in contact athletes.<sup>3</sup>

Glenoid rim fractures after suture anchor capsulolabral repairs are seen with use of both absorbable and nonabsorbable suture anchors. Fritsch et al<sup>18</sup> reported on 4 cases of glenoid rim fracture after arthroscopic anterior stabilizations, 1 of which employed nonabsorbable PEEK anchors. The resulting fractures after use of both types of anchors suggest that this complication may occur due to factors in addition to simple cyst formation around a degrading bioabsorbable anchor. The stress risers from pilot drill holes, their configuration, and the size and composition of the suture anchors may all play a potential role as factors.<sup>18</sup>

These rare complications of bioabsorbable suture anchors underscore the general safety and efficacy of their use. In 2008, 10 bioabsorbable suture anchor complications in or about the shoulder total were reported to the US Food and Drug Administration out of a total of 1 072 000 bioabsorbable suture anchors implanted in this same anatomic region, resulting in a complication rate of  $9.3 \times 10^{-4}\%$ .<sup>32,51</sup> This represents a "best-case scenario" as likely many cases go unreported. Excellent clinical results of surgical treatment of labral repair using bioabsorbable anchors have been reported, with success rates ranging from 71% to 97%.<sup>39,41,42</sup> Pagnani et al<sup>39</sup> reported on 22 patients with superior labral/biceps anchor repair using an arthroscopic technique and bioabsorbable suture anchors. At 2-year mean follow-up, satisfactory results were obtained in 86% of patients. Of the patients who did not do well, 2 patients continued to complain of



**Figure 2.** A, T2-weighted sagittal MRI view of the left glenoid in a patient with anchor-induced glenoid chondrolysis. Arrows point to multiple cysts along the posterior aspect of the glenoid. B, coronal CT view of the left glenohumeral joint in a patient with anchor-induced glenohumeral chondrolysis. Arrows point to multiple cystic anchor tracts within the glenoid.

pain, and 3 had restricted motion. None of these outcomes were attributed to failure or complication of the suture anchors.<sup>39</sup> Samani et al<sup>41</sup> reported on 25 patients with type II SLAP repairs using an arthroscopic technique and absorbable anchors. Eighty-eight percent of patients in this series had successful repair, with mean American Shoulder and Elbow Surgeons score improvement from 45 preoperatively to 92 postoperatively. All but 2 patients were able to return to their preinjury levels of sports participation. No complications or failures of the bioabsorbable suture anchors were reported.<sup>41</sup>

Magnusson et al<sup>30</sup> reported on a clinical and radiographic review of 18 consecutive patients in whom absorbable anchors were used for open Bankart repair. All patients in this series were recurrent, unidirectional, posttraumatic shoulder instability cases. In the majority of patients (15/18), a stable shoulder was obtained, and the drill holes in which the anchors were placed were deemed invisible or hardly visible in 12 of 18 (67%) patients.<sup>30</sup> The TAG anchor (Smith and Nephew, Andover, Massachusetts) was used in all cases. This implant has been shown in vivo to lose strength at a rate of approximately 25% per week. Despite this rapid absorption, Rowe and Constant scores on average were found to be 94 points (range, 63-100 points) and 88.5 points (range, 65-100 points), respectively, at 90 months.<sup>30</sup>

Warne et al<sup>54</sup> reported on the prospective, randomized comparison of absorbable versus nonabsorbable (polymer) anchors used during open Bankart repair. In the 40 patients

in this trial randomized to both groups, no difference was found in subjective or objective scores between groups. Two failures were noted in the group reconstructed with absorbable anchors and 1 in the group with nonabsorbable anchors.

Like bioabsorbable anchors, the exact number of complications is not documented in a central database for comparison; review of the literature on the subject demonstrates no significant difference between the complication rates of bioabsorbable suture anchors and nonabsorbable anchors.<sup>15,23,31</sup> In a comparative cohort study, Ejerhed et al<sup>15</sup> not only demonstrated that there is no difference in outcomes between absorbable and absorbable anchors, they also documented similar cystic changes in both groups on follow-up radiographs. In a recent randomized control trial, Milano et al<sup>31</sup> showed no difference in complications or a difference in validated outcome measures.

Regardless of suture anchor material, meticulous insertion technique must be followed, and if not followed, the absorptive ability of the suture anchor will certainly not prevent failure of the device or the repair. Barber<sup>4</sup> noted that the common modes of anchor failure include not burying the anchor deep enough to cover the eyelet in bone, anchor migration after insertion (due to excessive decortication, for instance), anchor loosening due to overaggressive rehabilitation, and anchor breakage during insertion. Wong et al<sup>56</sup> discuss attentiveness to the proper insertion angle to prevent intra-articular protrusion. Emphasis on proper techniques including anchor insertion to the appropriate depth, angle, and location may help prevent anchor-related glenohumeral complications, whether bioabsorbable or not. Indeed, as Cole and Provencher<sup>14</sup> state, the technical issues related to anchor placement cannot be overemphasized and may limit the failure of bioabsorbable anchors.

## CONCLUSION

Recently, bioabsorbable suture anchors have been used for many applications in shoulder surgery in which soft tissue is surgically coapted to bone. The development of bioabsorbable suture anchors has provided surgeons with an absorbable device with comparable strength and efficacy to metal implants. Recent reports of complications associated with these new anchors highlight the importance of early recognition of anchor-related problems in and around the glenohumeral joint. Patients with anchor-related glenohumeral pathology can present almost 2 years after index surgery with symptoms of pain or stiffness. Potential complications include foreign body reactions, osteolysis, synovitis, chondrolysis, and implant failure. Recognition and adherence to proper anchor insertion techniques should be paramount in shoulder arthroscopic surgery, regardless of manufacturing material of the suture anchor. Meticulous surgical technique may obviate many potential complications. Based on paucity of literature reports of complications with bioabsorbable suture anchors about the shoulder despite the thousands implanted every year, it is our belief, based on the literature presented, that these anchors provide a safe and mechanically stable implant, allowing arthroscopic surgeons to reliably repair soft tissue to bone in and around the shoulder.

An online CME course associated with this article is available for 1 *AMA PRA Category 1 Credit*<sup>TM</sup> at <http://ajsm-cme.sagepub.com>. In accordance with the standards of the Accreditation Council for Continuing Medical Education (ACCME), it is the policy of The American Orthopaedic Society for Sports Medicine that authors, editors, and planners disclose to the learners all financial relationships during the past 12 months with any commercial interest (A 'commercial interest' is any entity producing, marketing, re-selling, or distributing health care goods or services consumed by, or used on, patients). Any and all disclosures are provided in the online journal CME area which is provided to all participants before they actually take the CME activity. In accordance with AOSSM policy, authors, editors, and planners' participation in this educational activity will be predicated upon timely submission and review of AOSSM disclosure. Non-compliance will result in an author/editor or planner to be stricken from participating in this CME activity.

## REFERENCES

1. Athanasiou KA, Agrawal CM, Barber FA, Burkhart SS. Orthopaedic applications for PLA-PGA biodegradable polymers. *Arthroscopy*. 1998;14(7):726-737.
2. Athwal GS, Shridharani SM, O'Driscoll SW. Osteolysis and arthropathy of the shoulder after use of bioabsorbable knotless suture anchors: a report of four cases. *J Bone Joint Surg Am*. 2006;88(8):1840-1845.
3. Banerjee S, Weiser L, Connell D, Wallace AL. Glenoid rim fracture in contact athletes with absorbable suture anchor reconstruction. *Arthroscopy*. 2009;25(5):560-562.
4. Barber FA. Biodegradable shoulder anchors have unique modes of failure. *Arthroscopy*. 2007;23(3):316-320.
5. Barber FA. Biology and clinical experience of absorbable materials in ACL fixation. *Tech Orthop*. 1999;14:34-42.
6. Barber FA, Dockery WD. Long-term absorption of poly-L-lactic acid interference screws. *Arthroscopy*. 2006;22(8):820-826.
7. Barber FA, Snyder SJ, Abrams JS, Fanelli GC, Savoie FH 3rd. Arthroscopic Bankart reconstruction with a bioabsorbable anchor. *J Shoulder Elbow Surg*. 2003;12(6):535-538.
8. Boden RA, Burgess E, Enion D, Srinivasan MS. Use of bioabsorbable knotless suture anchors and associated accelerated shoulder arthropathy: report of 3 cases. *Am J Sports Med*. 2009;37(7):1429-1433.
9. Brantigan JW, McAfee PC, Cunningham BW, Wang H, Orbegoso CM. Interbody lumbar fusion using a carbon fiber cage implant versus allograft bone: an investigational study in the Spanish goat. *Spine*. 1994;19(13):1436-1444.
10. Brantigan JW, Steffee AD. A carbon fiber implant to aid interbody lumbar fusion: two-year clinical results in the first 26 patients. *Spine*. 1993;18(14):2106-2107.
11. Brantigan JW, Steffee AD, Lewis ML, Quinn LM, Persenaire JM. Lumbar interbody fusion using the Brantigan I/F cage for posterior lumbar interbody fusion and the variable pedicle screw placement system: two-year results from a Food and Drug Administration investigational device exemption clinical trial. *Spine*. 2000;25(11):1437-1446.
12. Briem D, Strametz S, Schröder K, et al. Response of primary fibroblasts and osteoblasts to plasma treated polyetheretherketone (PEEK) surfaces. *J Mater Sci Mater Med*. 2005;16(7):671-677.
13. Burkhart S, Lo IKY. Arthroscopic rotator cuff repair. *J Am Acad Orthop Surg*. 2006;14(6):333-346.
14. Cole B, Provencher MT. Safety profile of bioabsorbable shoulder anchors. *Arthroscopy*. 2007;23(8):912-914.



15. Ejerhed L, Kartus J, Funck E, Kohler K, Sernert N, Karlsson J. A clinical and radiographic comparison of absorbable and non-absorbable suture anchors in open shoulder stabilisation. *Knee Surg Sports Traumatol Arthrosc.* 2000;8(6):349-355.
16. Frazza EJ, Schmitt EE. A new absorbable suture. *J Biomed Mater Res.* 1971;5(2):43-58.
17. Freehill MQ, Harms DJ, Huber SM, Atlihan D, Buss DD. Poly-L-lactic acid tack synovitis after arthroscopic stabilization of the shoulder. *Am J Sports Med.* 2003;31(5):643-647.
18. Fritsch BA, Arciero RA, Taylor DC. Glenoid rim fracture after anchor repair. *Am J Sports Med.* 2010;38(8):1682-1686.
19. Gaenslen ES, Satterlee CC, Hinson GW. Magnetic resonance imaging for evaluation of failed repairs of the rotator cuff. *J Bone Joint Surg Am.* 1996;78(9):1391-1396.
20. Glueck D, Wilson TC, Johnson DL. Extensive osteolysis after rotator cuff repair with a bioabsorbable suture anchor: a case report. *Am J Sports Med.* 2005;33(5):742-744.
21. Goeminne S, Debeer P. Delayed migration of a metal suture anchor into the glenohumeral joint. *Acta Orthop Belg.* 2010;76:834-837.
22. Gunja NJ, Athanasiou KA. Biodegradable materials in arthroscopy. *Sports Med Arthrosc.* 2006;14(3):112-119.
23. Haviv B, Dolev E, Haber M, Mayo L, Biggs D. Arthroscopic rotator cuff repair: clinical outcome of 607 patients. *Knee Surg Sports Traumatol Arthrosc.* 2010;18(12):1707-1711.
24. Hecker AT, Shea M, Hayhurst JO, Myers ER, Meeks WL, Hayes WC. Pull-out strength of suture anchors for rotator cuff and Bankart lesion repairs. *Am J Sports Med.* 1993;21(6):874-879.
25. Kaar TK, Schenck RC, Wirth MA, Rockwood CA Jr. Complications of metallic suture anchors in shoulder surgery: a report of 8 cases. *Arthroscopy.* 2001;17(1):31-37.
26. Kelly JD 2nd. Disintegration of an absorbable rotator cuff anchor six weeks after implantation. *Arthroscopy.* 2005;21(4):495-497.
27. Kurtz SM, Devine JN. PEEK biomaterials in trauma, orthopedic, and spinal implants. *Biomaterials.* 2007;28(32):4845-4869.
28. Lajtai G, Schmiedhuber G, Unger F, et al. Bone tunnel remodeling at the site of biodegradable interference screws used for anterior cruciate ligament reconstruction. *Arthroscopy.* 2001;17(6):597-602.
29. Ma CB, Francis K, Towers J, Irrgang J, Fu FH, Harner CH. Hamstring anterior cruciate ligament reconstruction: a comparison of bioabsorbable interference screw and endobutton-post fixation. *Arthroscopy.* 2004;20(2):122-128.
30. Magnusson L, Ejerhed L, Rostgrd L, Sernert N, Kartus J. Absorbable implants for open shoulder stabilization: a 7-8-year clinical and radiographic follow-up. *Knee Surg Sports Traumatol Arthrosc.* 2006;14(2):182-188.
31. Milano G, Grasso A, Salvatore M, Saccomanno MF, Deriu L, Fabbriani C. Arthroscopic rotator cuff repair with metal and biodegradable suture anchors: a prospective randomized study. *Arthroscopy.* 2010;26(9 suppl):S112-S119.
32. Millennium Research Group. US markets for arthroscopy devices 2009. Available at: <http://mrg.net/Products-and-Services/Syndicated-Report.aspx?r=RPUS30AR09>. Accessed July 13, 2011.
33. Muller M, Kaab MJ, Villiger C, Holzach P. Osteolysis after open shoulder stabilization using a new bio-resorbable bone anchor: a prospective, non-randomized clinical trial. *Injury.* 2002;33(suppl 2):B30-B36.
34. Nho SJ, Provencher MT, Seroyer ST, Romeo AA. Bioabsorbable anchors in glenohumeral shoulder surgery. *Arthroscopy.* 2009;25(7):788-793.
35. Nho SJ, Yadav H, Pensak M, Dodson CC, Good CR, MacGillivray JD. Biomechanical fixation in arthroscopic rotator cuff repair. *Arthroscopy.* 2007;23(1):94-102, 102.e1.
36. Noiset O, Schneider YJ, Marchand-Brynaert J. Fibronectin adsorption or/and covalent grafting on chemically modified PEEK film surfaces. *J Biomater Sci Polym Ed.* 1999;10(6):657-677.
37. Nusselt T, Freche S, Klinger HM, Baums MH. Intraosseous foreign body granuloma in rotator cuff repair with bioabsorbable suture anchor. *Arch Orthop Trauma Surg.* 2010;130(8):1037-1040.
38. Ozbaydar M, Elhassan B, Warner JJP. The use of anchors in shoulder surgery: a shift from metallic to bioabsorbable anchors. *Arthroscopy.* 2007;23(10):1124-1126.
39. Pagnani MJ, Speer KP, Altchek DW, Warren RF, Dines DM. Arthroscopic fixation of superior labral lesions using a biodegradable implant: a preliminary report. *Arthroscopy.* 1995;11(2):194-198.
40. Petricca SE, Marra KG, Kumta PN. Chemical synthesis of poly (lactic-co-glycolic acid)/hydroxyapatite composites for orthopaedic applications. *Acta Biomater.* 2006;2(3):277-286.
41. Samani JE, Marston SB, Buss DD. Arthroscopic stabilization of type II SLAP lesions using an absorbable tack. *Arthroscopy.* 2001;17(1):19-24.
42. Sassmannshausen G, Sukay M, Mair SD. Broken or dislodged poly-L-lactic acid bioabsorbable tacks in patients after SLAP lesion surgery. *Arthroscopy.* 2006;22(6):615-619.
43. Silver MD, Daigneault JP. Symptomatic interarticular migration of glenoid suture anchors. *Arthroscopy.* 2000;16(1):102-105.
44. Siparski PN, Gramen P, Gall K, D'Ambrosia R. Bioabsorbable polymers used in knee arthroscopy, part I: basic science and application. *Tech Knee Surg.* 2006;5:193-198.
45. Speer KP, Warren RF. Arthroscopic shoulder stabilization: a role for biodegradable materials. *Clin Orthop Relat Res.* 1993;291:67-74.
46. Speer KP, Warren RF, Pagnani M, Warner JJ. An arthroscopic technique for anterior stabilization of the shoulder with a bioabsorbable tack. *J Bone Joint Surg Am.* 1996;78(12):1801-1807.
47. Spoliti M. Glenoid osteolysis after arthroscopic labrum repair with a bioabsorbable suture anchor. *Acta Orthop Belg.* 2007;73(1):107-110.
48. Stähelin AC, Weiler A, Rüfenacht H, Hoffmann R, Geissmann A, Feinstein R. Clinical degradation and biocompatibility of different bioabsorbable interference screws: a report of six cases. *Arthroscopy.* 1997;13(2):238-244.
49. Toth JM, Wang M, Estes BT, et al. Polyetheretherketone as a biomaterial for spinal applications. *Biomaterials.* 2006;27(3):324-334.
50. Tuoheti Y, Itoi E, Yamamoto N, et al. Contact area, contact pressure, and pressure patterns of the tendon-bone interface after rotator cuff repair. *Am J Sports Med.* 2005;33(12):1869-1874.
51. US Food and Drug Administration. Medical devices. US Department of Health & Human Services Web site. <http://www.fda.gov/MedicalDevices/default.htm>. Accessed September 21, 2010.
52. Viljanen JT, Pihlajamäki HK, Törmälä PO, Rokkanen PU. Comparison of the tissue response to absorbable self-reinforced polylactide screws and metallic screws in the fixation of cancellous bone osteotomies: an experimental study on the rabbit distal femur. *J Orthop Res.* 1997;15(3):398-407.
53. Warden WH, Chooljian D, Jackson DW. Ten-year magnetic resonance imaging follow-up of bioabsorbable poly-L-lactic acid interference screws after anterior cruciate ligament reconstruction. *Arthroscopy.* 2008;24(3):370.e1-370.e3.
54. Warme WJ, Arciero RA, Savoie FH, Uhorchak JM, Walton M. Nonabsorbable versus absorbable suture anchors for open Bankart repair. *Am J Sports Med.* 1999;27(6):742-746.
55. Willcox N, Roberts S. Delayed biodegradation of a meniscal screw. *Arthroscopy.* 2004;20:20-22.
56. Wong AS, Kokkalis ZT, Schmidt CC. Proper insertion angle is essential to prevent intra-articular protrusion of a knotless suture anchor in shoulder rotator cuff repair. *Arthroscopy.* 2010;26(2):286-290.
57. Yahiro MA, Matthews LS. Arthroscopic stabilization procedures for recurrent anterior shoulder instability. *Orthop Rev.* 1989;18(11):1161-1168.
58. Zantop T, Weimann A, Schmidtko R, et al. Graft laceration and pull-out strength of soft-tissue anterior cruciate ligament reconstruction: in vitro study comparing titanium, poly-d,l-lactide, and poly-d,l-lactide-tricalcium phosphate screws. *Arthroscopy.* 2006;22(11):1204-1210.